Anatomy Review:

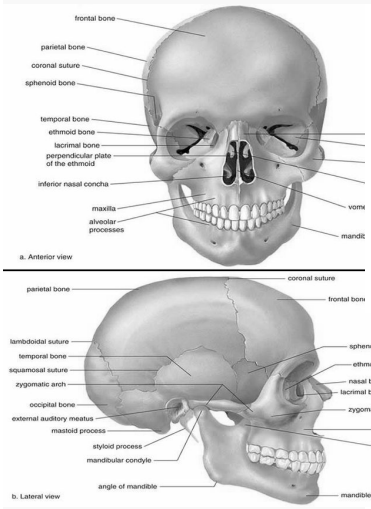

Skull:

22 bones (excluding ossicles of ear)

Bones attached by *sutures* (immovable) and make up the *cranium*

Cranium: Upper part, surrounds cranial cavity

Facial Skeleton: Lower ant. part

Calvaria: Paired Temporal bones, Paired Parietal bones, Frontal, Sphenoid, Ethmoid and Occipital bones.

Facial: Paired Nasal bones, Paired Zygomatic bones, Paired Palatine bones, Paired Lacrimal bones, Paired Maxillae, Paired Inter Nasal Conchae and Vomer.

MANDIBLE = NOT PART OF CRANIUM OR FACIAL SKELETON

Skull Anatomy: Inferior View

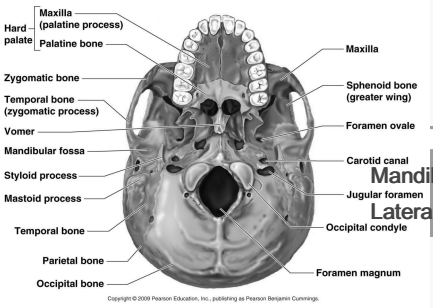

Forehead: Landmarks

> Frontal Bone	> Supraciliary Arches
> Glabella	> Supra-orbital Foramen/notch
>Zygomatic process of Frontal Bone	> Frontal Process of Zygomatic Bone

Zygomatic and Nasal Bones:

Lower lateral rim of orbit and lateral part of inferior rim of orbit = formed by **Zygomatic Bone**

Landmarks:

> Frontal Nasal Suture (formed by articulation of nasal bones)

> Nasion	> Frontal Process of Maxilla
> Piriform Apenture	> Nasal Crests
> Nasal Septum	> Anterior Nasal Spine

> Paired Inferior Nasal Conchae

Mandible: Medial View

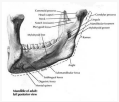

Mandible: External Surface Lateral View

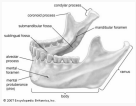

Mandible: Internal Surface

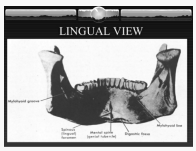

Mandible:

Most inferior structure in ant. view of skull

Consists of: Body (ant.) and Ramus (post) - these 2 meet at angle of mandible

Body: > **Lower Part:** base - has midline swelling (mental protuberance) where 2 left and right sides meet. >**Upper part:** Alveolar segment (contains teeth and tooth sockets)

Mental foramen: visible between upper and border, between 1st and 2nd premolars, openings on ext. surface, passage for mental nerves and blood vessels.

Oblique Ridge: passes from ramus onto body, point of attachment for muscles that depress lower lip.

Mandible: (cont)

Condyler Process: Involved in articulation of mand. w/ glenoid fossa and temporal bone.

Coronoid Process: Thin upward projections on ant. surface of ramus, attachment for temporalis muscle

Mandibular Notch: Depress between coronoid processes and condyles

Mandibular Foramen: Opening on inner surface of body, allow passage of Alveloar nerves and blood vessels.

Lingula: Attachment for mandibular end of Sphenomandibular ligament

Mandibular Symphasis: Verticle midline fusion between 2 embryonic ossification centers (form body).

Mylohyoid Groove

Rami: Flattened, projected upwards

Angle: Where body joins ramus

Maxilla: Sagittal View

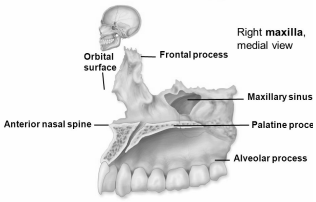

Maxilla: Medial Frontal view

Sponsored by **Readable.com**
Measure your website readability!
https://readable.com

Maxilla:

Part of face, between orbit and upper teeth

Upper jaw is formed by: Paired Maxillae

Contribute superiorly to inferior and medial rims of orbit

Zygomatic process = articulates with Zygomatic bone (medially)

Frontal process = articulates with frontal bone

Landmarks:

> Body of Maxilla
> Infra Orbital Foramen
> Alveolar Process

Hard Palate:

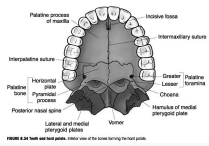

FIGURE 8.24 Teeth and hard palate. Inferior view of the bones forming the hard palate.

Sponsored by **Readable.com**
Measure your website readability!
https://readable.com